

# Poultry Special Edition

# CAHFS

# CONNECTION

January 2012

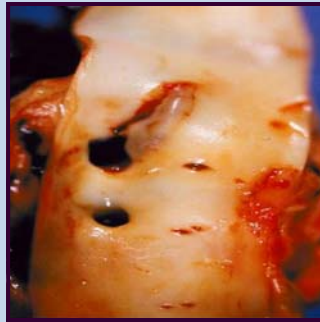
## Inside this issue:

- ◆ **Aortic Rupture in Male Turkeys**
- ◆ **Histomoniasis**
- ◆ **Infectious Bronchitis**
- ◆ **Infectious Laryngotracheitis**
- ◆ **Mycoplasmosis**
- ◆ **Riemerella Anatipestifer Infection**



Not receiving CAHFS Connection directly?  
Contact Sharon Hein  
at [shein@ucdavis.edu](mailto:shein@ucdavis.edu)

## Aortic Rupture in Male Turkeys (AR)

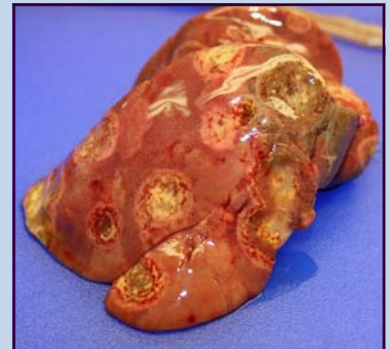

Tear in abdominal aorta of male turkey

AR, first described in the U.S. in 1959, occurs sporadically in growing male turkeys. During 2001 and again in 2011, AR outbreaks occurred on many ranches in California's Central Valley, affecting commercial flocks of male turkeys at 14 - 20 weeks of age. Histories included sudden death, excessive mortality ranging from 0.75% to 1.5% per week, and increased numbers of turkeys dead on arrival at processing plants. Related female turkeys on similar diets were not affected. Necropsy of affected birds revealed large amounts of clotted blood in the abdominal cavity and linear tears in the abdominal aorta (see picture). Histologically, most aortas showed thickening, degeneration, necrosis, and hemorrhage; special stains revealed abnormal elastic fibers and collagen in these tissues. The cause of aortic rupture could not be determined; however, a genetic basis is suspected.

## Histomoniasis

Histomoniasis, commonly known as "blackhead", is a very important parasitic disease involving many species of gallinaceous birds particularly turkeys. *Histomonas meleagridis*, the causative agent of Histomoniasis, is a protozoan that can be closely associated with the cecal worm *Heterakis gallinarum*, which harbors *H. meleagridis*. *H. meleagridis* can be transmitted indirectly via ingestion of *H. gallinarum* embryonated eggs, which can contaminate the environment including feed and water. Earthworms can concentrate *H. gallinarum* larvae and histomonads and ingestion of these nematodes can also lead to disease. *H. meleagridis* can be transmitted directly through contact with fresh feces from sick birds. Clinical signs of histomoniasis in turkeys include sulfur yellow feces, depression, drooping wings, tucked heads, anorexia and loose feces; mortality can reach 70%. Necropsy lesions are most striking in the ceca and liver, demonstrating cores of caseous exudate and necrotic nodules (see picture). In chickens, the disease may vary from subclinical infection to severe illness with high mortality. Histomoniasis can be diagnosed histologically by demonstrating the presence of protozoal organisms associated with compatible lesions in the liver and ceca. Currently there are no effective drugs labeled to treat for this disease.



Turkey liver with multifocal lesions

## CAHFS Lab Locations

### CAHFS - Davis

University of California  
West Health Sciences Drive  
Davis, CA 95616  
Phone: 530-752-8700  
Fax: 530-752-6253

[cahfsdavis@cahfs.ucdavis.edu](mailto:cahfsdavis@cahfs.ucdavis.edu)

### CAHFS - San Bernardino

105 W. Central Avenue  
San Bernardino, CA 92408  
Phone: (909) 383-4287  
Fax: (909) 884-5980

[cahfsanbernardino@cahfs.ucdavis.edu](mailto:cahfsanbernardino@cahfs.ucdavis.edu)

### CAHFS - Tulare

18830 Road 112  
Tulare, CA 93274  
Phone: (559) 688-7543  
Fax: (559) 686-4231

[cahfstulare@cahfs.ucdavis.edu](mailto:cahfstulare@cahfs.ucdavis.edu)

### CAHFS—Turlock

1550 Soderquist Road  
Turlock, CA 95381  
Phone: (209) 634-5837  
Fax: (209) 667-4261

[cahfsturlock@cahfs.ucdavis.edu](mailto:cahfsturlock@cahfs.ucdavis.edu)

---

---

Your feedback is always welcome. To provide comments or to get additional information on any of the covered topics or services, please contact Sharon Hein at [slhein@ucdavis.edu](mailto:slhein@ucdavis.edu).

---

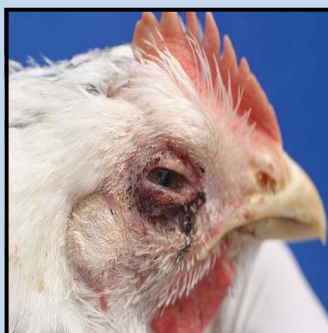---

We're on the Web  
[www.cahfs.ucdavis.edu](http://www.cahfs.ucdavis.edu)

### Infectious Bronchitis (IB)

IB is a common, highly contagious, economically important disease of chickens caused by a coronavirus, Infectious Bronchitis virus (IBV). In young growing chickens IBV causes respiratory disease while in broilers IBV is associated with reduced weight gain, reduced feed efficiency, and predisposition to bacterial infections. Mortality can be high in 5-6 week old birds. The virus can replicate in the oviduct, resulting in persistent damage in both immature and laying hens and reducing lifetime egg production. Egg shells are often misshapen, thin, and break easily; and the albumin is often watery. Some strains of IBV are nephropathogenic, capable of causing kidney induced mortality. Mutation and genetic recombination are common in IBV, resulting in a variety of serotypes with altered pathogenicity and limiting the efficacy of vaccination. IB can be diagnosed using serology, PCR, and virus isolation/sequencing. Currently in California, the incidence of IB is low; with serotypes Connecticut and a variant known as CAL 99 being the most frequently diagnosed.

### Infectious Laryngotracheitis (ILT)



Conjunctivitis in a chicken with ILT

ILT, caused by Gallid Herpesvirus 1, is a respiratory disease primarily affecting chickens of all ages. The disease is characterized by ocular and nasal discharge, gasping, and death, with lesions most commonly seen in the conjunctiva and upper respiratory tract (see picture). Presumptive diagnosis of ILT can be obtained using histopathology and fluorescent antibody (FA) testing. ILT infections can be controlled with proper vaccination by the eye-drop method; however use of live vaccines for ILT is not advised as the vaccine virus can revert to virulence resulting in disease in susceptible birds. Strict biosecurity, cleaning and disinfection of premises, and increased down time between placement of each flock will help prevent ILT infections.

### Mycoplasmosis

Mycoplasmosis represents a costly disease concern in commercial poultry. The four main pathogenic mycoplasmas are *Mycoplasma gallisepticum* (MG), *Mycoplasma iowae* (MI), *Mycoplasma meleagridis* (MM) and *Mycoplasma synoviae* (MS). MG, can infect chickens, turkeys and other avian species, causing the most significant losses. In young meat birds, MG primarily affects the respiratory system, leading to airsacculitis, sinusitis and increased condemnation in processing plants. Laying hens show mild to moderate decreases in egg production. MG is contagious between birds and can be spread transovarially from an infected hen to her progeny. Strict biosecurity is critical to prevent introduction and limit spread of MG throughout the ranch and to other facilities. Diagnosis is made by serology, PCR, culture and/or immunohistochemistry; molecular characterization may provide additional epidemiologic information. Vaccines are available, but are not considered economically feasible for use in meat birds. Eradication is considered the best control strategy for mycoplasmosis in most commercial poultry flocks.

### *Riemerella anatipestifer* (RA) infection

One of the most common diseases of young commercial ducks is septicemia associated with RA. Other species of birds such as geese and turkeys are also susceptible. The disease is characterized by listlessness, coughing, ocular and nasal discharge and ataxia. Polyserositis, including pericarditis, perihepatitis, airsacculitis, pleuritis and meningitis, is common in RA infections. There are numerous serotypes of RA making it difficult to control the disease by vaccination. Antibiotics are effective in treating RA infections.



Ducks infected with *R. anatipestifer* exhibiting neurological signs